JOURNAL OF THE AMERICAN COLLEGE OF CARDIOLOGY
VOL. 82, NO. 20, 2023

PUBLISHED BY ELSEVIER

THE PRESENT AND FUTURE

JACC STATE-OF-THE-ART REVIEW

Imaging Methods for Evaluation of Chronic Aortic Regurgitation in Adults

JACC State-of-the-Art Review

Lauren S. Ranard, MD,[a] Robert O. Bonow, MD,[b] Rick Nishimura, MD,[c] Michael J. Mack, MD,[d] Vinod H. Thourani, MD,[e] Joseph Bavaria, MD,[f] Patrick T. O'Gara, MD,[g] Jeroen J. Bax, MD, PhD,[h] Philipp Blanke, MD,[i] Victoria Delgado, MD, PhD,[j] Jonathon Leipsic, MD,[i] Roberto M. Lang, MD,[k] Hector I. Michelena, MD,[c] João L. Cavalcante, MD,[l] Torsten P. Vahl, MD,[a] Martin B. Leon, MD,[a] Vera H. Rigolin, MD,[b] on behalf of the Heart Valve Collaboratory

ABSTRACT

A global multidisciplinary workshop was convened to discuss the multimodality diagnostic evaluation of aortic regurgitation (AR). Specifically, the focus was on assessment tools for AR severity and analyzing evolving data on the optimal timing of aortic valve intervention. The key concepts from this expert panel are summarized as: 1) echocardiography is the primary imaging modality for assessment of AR severity; however, when data is incongruent or incomplete, cardiac magnetic resonance may be helpful; 2) assessment of left ventricular size and function is crucial in determining the timing of intervention; 3) recent evidence suggests current cutpoints for intervention in asymptomatic severe AR patients requires further scrutiny; 4) left ventricular end-systolic volume index has emerged as an additional parameter that has promise in guiding timing of intervention; and 5) the role of additional factors (including global longitudinal strain, regurgitant fraction, and myocardial extracellular volume) is worthy of future investigation.
(J Am Coll Cardiol 2023;82:1953–1966) © 2023 by the American College of Cardiology Foundation.

The prevalence of aortic regurgitation (AR) is not well established. Recent large-scale, community-based epidemiologic studies report greater than or equal to mild AR in 15% to 67.5% of adult patients ≥65 years of age, with male sex and increasing age being the primary risk factors for disease. Clinically significant AR (≥ moderate or 3+) is estimated to account for 1.6% to 15% of the AR population.[1,2]

In most patients, AR is due to chronic degenerative disease and almost one-half of the patients have congenital abnormalities, predominantly bicuspid

From the [a]Division of Cardiology, Columbia University Irving Medical Center, New York, New York, USA; [b]Division of Cardiology, Northwestern University Feinberg School of Medicine, Northwestern Memorial Hospital, Chicago, Illinois, USA; [c]Department of Cardiovascular Medicine, Mayo Clinic, Rochester, Minnesota, USA; [d]Division of Cardiothoracic Surgery, Heart Hospital Baylor Plano, Baylor Healthcare System, Plano, Texas, USA; [e]Department of Cardiovascular Surgery, Marcus Valve Center, Piedmont Heart Institute, Atlanta, Georgia, USA; [f]Division of Cardiovascular Surgery, University of Pennsylvania, Philadelphia, Pennsylvania, USA; [g]Division of Cardiovascular Medicine, Brigham and Women's Hospital, Boston, Massachusetts, USA; [h]Department of Cardiology, Leiden University Medical Centre, Leiden, the Netherlands; [i]Department of Radiology, St Paul's Hospital & University of British Columbia, Vancouver, British Columbia, Canada; [j]Department of Cardiology, Hospital University Germans Trias i Pujol, Badalona, Spain; [k]Section of Cardiology, Heart and Vascular Center, University of Chicago Medical Center, Chicago, Illinois, USA; and the [l]Division of Cardiology, Minneapolis Heart Institute, Abbott Northwestern Hospital, Minneapolis, Minnesota, USA.
Nakeya Dewaswala, MD, served as Guest Associate Editor for this paper. Christopher M. O'Connor, MD, served as Guest Editor-in-Chief for this paper.
The authors attest they are in compliance with human studies committees and animal welfare regulations of the authors' institutions and Food and Drug Administration guidelines, including patient consent where appropriate. For more information, visit the Author Center.

Manuscript received June 20, 2023; accepted August 21, 2023.

Listen to this manuscript's audio summary by Editor-in-Chief Dr Valentin Fuster on www.jacc.org/journal/jacc.

ISSN 0735-1097/$36.00
https://doi.org/10.1016/j.jacc.2023.08.051

JACC VOL. 82, NO. 20, 2023
NOVEMBER 14, 2023:1953–1966

ABBREVIATIONS AND ACRONYMS

2D = 2-dimensional

3D = 3-dimensional

AR = aortic regurgitation

CMR = cardiac magnetic resonance

CT = computed tomography

ECV = extracellular volume

GLS = global longitudinal strain

LV = left ventricle

LVEDD = left ventricular internal end-diastolic dimension

LVEDV = left ventricular end-diastolic volume

LVEF = left ventricular ejection fraction

LVESD = left ventricular end-systolic dimension

LVESV = left ventricular end-systolic volume

RF = regurgitant fraction

ROA = regurgitant orifice area

RV = regurgitant volume

TEE = transesophageal echocardiography

TTE = transthoracic echocardiography

aortic valves.[3,4] Patients with AR and bicuspid valve disease are younger by 2 decades, primarily male, and commonly have associated ascending aortic dilation.[5,6]

The pathophysiology of AR is complex; over time excessive preload and afterload portend to eccentric left ventricular (LV) hypertrophy and dilation. In turn, this leads to diastolic and microvascular dysfunction and interstitial cellular changes. Disease progression is multifactorial and predicted by ventricular response, age, genetics, and concomitant comorbidities (such as hypertension). The longstanding pressure and volume overload can result in marked LV dilation, irreversible LV systolic dysfunction, and eventually heart failure symptoms, all of which are associated with a poor prognosis.[7] Ideally, aortic valve intervention is performed before the onset of irreversible remodeling and/or LV systolic dysfunction.

Currently, the presence of symptoms, left ventricular ejection fraction (LVEF), and echocardiographic linear LV dimensions guide the timing of intervention in patients with chronic severe AR. The contemporary recommendations from the American College of Cardiology/American Heart Association and European Society of Cardiology/European Association of Cardio-Thoracic Surgery practice guidelines for patients with valvular heart disease are summarized in **Table 1**.[8,9] However, recent data suggest that excess mortality may occur at lower thresholds of LV size and function.

The optimal timing of intervention for patients with asymptomatic significant AR is based on assessment of AR severity and identification of early signs of LV dysfunction and/or LV chamber dilation. Although echocardiography is the cornerstone imaging modality for assessment of patients with AR, multimodality imaging is crucial in many patients for complete assessment of AR severity and subclinical LV changes.

As such, the aim of this paper is to provide an overview of the key aspects of noninvasive imaging in the evaluation of chronic, native valve AR, and to readdress the parameters to determine timing of aortic valve intervention considering recent evidence that has emerged since the current guidelines. Herein, the data presented may serve as a stimuli for additional investigation to influence future guidelines.

HIGHLIGHTS

- Assessing the hemodynamic impact of AR on the LV involves integrating various imaging parameters pertaining to LV size and systolic function to determine the optimum time for intervention.
- Conventional criteria for surgical intervention in patients with AR include: LVEF ≤55%, LVESD ≥25 mm/m^2, progressive decline in LVEF to 55% to 60%, or increase in LVEDD to >65 mm.
- Additional studies are needed to determine whether lower thresholds (eg, LVEF <60% and LVESD >20 mm/m^2) for valve intervention would improve long-term outcomes for patients with chronic, severe AR.

METHODS

The Heart Valve Collaboratory AR working group is comprised of a diverse group of stakeholders and academic AR experts including international academic leaders and clinical investigators, industry, the U.S. Food and Drug Administration, the National Institutes of Health, and the U.S. Centers for Medicare and Medicaid Services.[10] The Heart Valve Collaboratory convened a global consortium in January 2022 to critically analyze the diagnostic evaluation of AR and address the current uncertainties, evidence gaps, and controversies in the timing of treatment of AR.

DIAGNOSTIC TOOLS FOR VALVE ASSESSMENT AND EVALUATION OF AR SEVERITY

PHYSICAL EXAMINATION. Attention to the physical examination and vital signs is necessary as the findings can be notable in significant AR, and can alert the clinician to a significant valve lesion for which further evaluation is needed. Physical examination findings include wide pulse pressure, low diastolic blood pressure, prominent holodiastolic murmur, bounding pulses on palpation, Corrigan sign, and Quincke's pulse.[11] Often the systolic outflow murmur from the increased forward stroke volume is more prominent than the diastolic murmur. Some of these findings are also associated with an increased mortality risk; in fact, decreasing diastolic blood pressure alone is an independent risk factor for mortality in chronic AR.[12]

ECHOCARDIOGRAPHY. Transthoracic echocardiography (TTE) is the initial and most commonly used modality

TABLE 1 ACC/AHA and ESC/EACTS Practice Guidelines for the Management of Patients With Chronic AR

ESC/EACTS	ACC/AHA
Class I	
(a) Surgery is recommended in symptomatic patients regardless of LV function (LOE: B)	
(b) Surgery is recommended in asymptomatic patients with LVESD >50 mm or LVESDi >25 mm/m^2 or LVEF ≤50% (LOE: B)	(b) Surgery is recommended in chronic, severe AR patients with LVEF ≤55% if no other cause of systolic dysfunction is identified (LOE: B)
(c) Surgery is recommended in symptomatic or asymptomatic patients with severe AR if undergoing CABG or surgery of ascending aorta or another valve (LOE: C)	
(d) Valve sparing root replacement is recommended in young patients with aortic root dilation, if performed in experienced centers and durable results are expected (LOE: B)	
(e) Ascending aortic surgery is recommended in patients with Marfan syndrome who have aortic root disease with maximal ascending aortic diameter ≥50 mm (LOE: C)	
Class IIa	
(a) Ascending aortic surgery should be considered in patients who have aortic root disease with maximal ascending aortic diameter: 1) ≥55 mm in all patients; or 2) ≥45 mm in the presence of Marfan syndrome or additional risk factors, or (3) ≥50 mm in the presence of bicuspid aortic valve with additional risk factors or coarctation (LOE: C)	(a) Surgery is reasonable in asymptomatic severe AR patients with LVEF >55% if LV is severely enlarged (LVESD >50 mm or LVESDi >25 mm/m^2) (LOE: B)
(b) When surgery is indicated for the aortic valve, replacement of the aortic root or tubular ascending aorta should be considered when ≥45 mm (LOE: C)	(b) Surgery is reasonable in patients with moderate AR who are undergoing cardiac or aortic surgery for other indications (LOE: C)
Class IIb	
(a) Surgery may be considered in asymptomatic patients with LVESDi >20 mm/m^2 or resting LVEF ≤55%, if surgery is low risk (LOE: C)	(a) Surgery may be considered in asymptomatic, severe AR patients with LVEF >55% who are low surgical risk and have a progressive decline in LVEF on at least 3 serial studies to the low-normal range (LVEF 55% to 60%) or a progressive increase in LV size into the severe range (LVEDD >65 mm) (LOE: B)
(b) Aortic valve repair may be considered in selected patients at experienced centers when durable results are expected (LOE: C)	

ACC = American College of Cardiology; AHA= American Heart Association; AR = aortic regurgitation; CABG = coronary artery bypass grafting; ESC = European Society of Cardiology; EACTS = European Association of Cardio-Thoracic Surgery; LOE = level of evidence; LV = left ventricular; LVEF = left ventricular ejection fraction; LVEDD = left ventricular end-diastolic dimension; LVESD = left ventricular end-systolic dimension; LVESDi = left ventricular end-systolic dimension index.

to evaluate cardiac structure and function in patients with all valvular disorders, including AR. A comprehensive TTE examination provides the mechanism and severity of the valve lesion, the hemodynamic impact of the valve lesion on the cardiac chambers, and the presence of other cardiac pathology. Two-dimensional (2D) assessment also includes a detailed evaluation of the aortic valve, the LV outflow tract, and the aorta to understand the anatomy and define the mechanism and severity of regurgitation.

Echocardiography is critical for determining the severity of AR. There are quantitative, semi-quantitative and qualitative methods using 2D TTE and Doppler techniques to assess AR severity.[13] No single method is preferred, and each has its pros and cons. Therefore, an integrated approach that combines methodologies is recommended (**Figure 1**). For example, holodiastolic reversal of flow in the abdominal aorta on TTE is a specific sign of severe AR; however, it cannot always be assessed using echocardiography due to body habitus or acoustic window limitations.

Transesophageal echocardiography (TEE) can be helpful in delineating leaflet morphology and evaluating the severity of AR when TTE image quality precludes accurate assessment. It also allows for a more detailed analysis for surgical aortic valve repair, valve sparing root repair, or transcatheter treatment options. Additional options for assessment in patients with suboptimal image quality or when discrepancies exist between echocardiographic and clinical data include cardiac magnetic resonance (CMR), cardiac computed tomography (CT) or aortic root angiography.

CMR. Both the American College of Cardiology/American Heart Association and European Society of Cardiology/European Association of Cardio-Thoracic Surgery guidelines recommend CMR as an adjunct diagnostic test in situations where echocardiography is inconclusive or further evaluation of AR severity is warranted.[8,9] CMR is able to accurately assess the mechanism of AR in addition to evaluation of atrioventricular morphology, aortic root, and thoracic aortic size.[14]

JACC VOL. 82, NO. 20, 2023
NOVEMBER 14, 2023:1953–1966

FIGURE 1 Echocardiographic Methods Used in the Assessment of AR Severity

Parameter	Example	Advantages	Limitations
Echocardiography			
Jet width/LVOT diameter Semiquantitative parameter	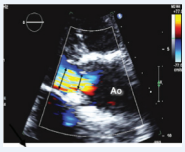	• Simple, sensitive screen • Rapid assessment • Jet width ≥65% of LVOT specific for severe AR	• Underestimates AR in eccentric jets • May overestimate AR in central or transient jets • Affected by LVOT size
Vena Contracta Semiquantitative parameter	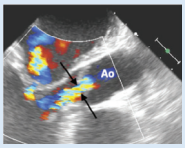	• Surrogate for regurgitant orifice size • May be used in eccentric jets • Independent of flow rate and driving pressure • Less dependent on technical factors • Good for identifying mild or severe AR; vena contracta width >0.6 cm specific for severe AR	• Problematic in the presence of multiple jets or bicuspid valves • Convergence zone needs to be visualized • Direction of the jet will influence the appearance of the jet
Proximal Flow Convergence Qualitative parameter	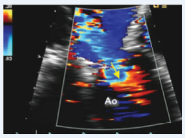	• Rapid assessment	• Less useful for multiple jets, constrained jet (by aortic wall), and nonhemispheric jet shapes • Timing in early diastole
Color Flow 3D Vena Contracta Quantitative parameter	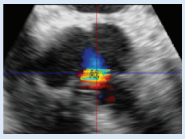	• Multiple jets of differing directions may be measured	• Dynamic jets may be over or underestimated
Pulsed-Wave Doppler: Flow Reversal in the Proximal Descending Aorta Qualitative parameter	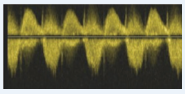	• Simple supportive sign of severe AR • More specific sign for severe AR if seen in the abdominal aorta • Can be obtained with TTE and TEE	• Depends on compliance of the aorta; less reliable in older patients • Brief velocity reversal is normal • Can be present in AV fistula in the upper extremity and ruptured sinus of Valsalva • May not be holodiastolic in acute AR
Density of Continuous-Wave Regurgitant Jet Qualitative parameter	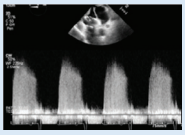	• Simple • Density proportional to number of red blood cells reflecting the signal • Faint or incomplete jet is compatible with mild or trace AR	• Perfectly central jets may appear denser than eccentric jets of higher severity • Overlap between moderate and severe AR
Pressure Half-Time Qualitative parameter	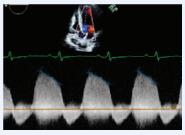	• Simple • Specific sign of pressure relation between aorta and LV; <200 ms is specific for severe AR	• Poor alignment of Doppler beam may result in lower pressure half time • Affected by changes that modify LV-aorta pressure gradient • Less useful in the assessment of chronic AR
Quantitative Doppler: EROA,RV, RF Quantitative parameter	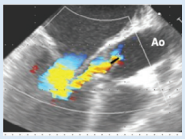	• Rapid quantitative assessment of lesion severity (EROA) and volume overload (RV)	• Feasibility limited by AV calcifications • Not valid for multiple jets • Less accurate in eccentric jets • Limited experience • Small errors in radius can lead to large errors in EROA due to squaring of error
Stroke Volume Method Quantitative parameter	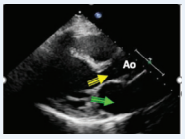	• Valid with multiple jets and eccentric jets • Provides lesion severity (EROA, RF) and volume overload (RV) • Can verify results using LV end diastolic volume and end-systolic volume	• Inaccuracies can result if there is difficulty measuring mitral annulus (eg, calcification) • Cannot be used for co-existing mitral and aortic regurgitation

An integrated approach using quantitative, semiquantitative and qualitative echocardiographic parameters is recommended to evaluate regurgitation severity. Adapted with permission from Zoghbi et al.[13] 3D = 3-dimensional; AR = aortic regurgitation; EROA = effective regurgitation orifice area; LV = left ventricle; LVOT = left ventricular outflow tract; RF = regurgitant fraction; RV = regurgitant volume; TEE = transesophageal echocardiography; TTE = transthoracic echocardiography.

Using 2D phase contrast CMR (ideally at the level of the sinotubular junction and perpendicular to the aorta), direct quantification of forward volume, regurgitant volume (RV) and regurgitant fraction (RF) can be performed (**Figure 2A**). Both CMR-RF and CMR-RV are highly reproducible and have superior reproducibility compared to echocardiography.[15] Formal cut-off values to delineate hemodynamically significant AR have yet to be defined. In the literature, the CMR-RF cut-off values that have best agreed with severe AR on echocardiography have ranged from 26% to 48%.[16-18] These CMR-RF cut-off values for significant AR are consistently lower than echocardiographic cut-offs and show better correlation with 3-dimensional (3D) TTE compared to 2D TTE.[19] A higher degree of AR severity by CMR is also associated with increased progression of symptoms and/or need for surgery with high accuracy. Using a cut-point value of a CMR-RF of 33%, Myerson et al[20] found that 85% of subjects with a CMR-RF >33% progressed to surgery in comparison to only 8% with a CMR-RF ≤33% ($P < 0.0001$). This was confirmed recently by Hashimoto et al[21] and by Faber et al[22] identifying a similar aortic CMR-RF threshold of 32% which was associated with symptom progression and/or need for aortic valve replacement.[21,22] Recent work by Vejpongsa et al[23] also supports a lower CMR-RF threshold (35%) for identification of severe AR as compared to the current proposed TTE-based guideline-threshold (RF >50%). Although an RF >50% is highly specific for significant AR, it may lack the needed sensitivity for earlier identification of LV remodeling and adverse outcomes.

In addition, holodiastolic retrograde flow at the proximal descending thoracic aorta can be easily assessed, is highly reproducible, and has prognostic value. The presence of holodiastolic retrograde flow on CMR is independently associated with 2.8 times increased risk of death or heart failure hospitalization.[17]

Despite the many advantages of CMR phase-contrast imaging in quantifying AR severity, such as its noninvasiveness and avoidance of contrast injection or radiation, important nuances are needed for its proper acquisition and analysis. First, systematic alignment of the imaging plane perpendicular to the vessel interrogated is essential to avoid underestimation of forward and regurgitation flows. Second, presence of mixed aortic stenosis and AR leads to dephasing and underestimation of forward flow. To overcome this limitation, a separate acquisition at the aortic annulus/left ventricular outflow tract (below the stenosis) and/or adjustment of the phase-contrast encoding velocity to avoid aliasing is necessary. Third, patients should be positioned at the magnet isocenter to minimize offset errors which can introduce up to 10% of variation in flow measurements, particularly if no background correction is applied.[24] Fourth, similar to echocardiography, CMR assessment of AR severity in the presence of atrial fibrillation requires averaging of multiple cardiac cycles with free-breathing phase-contrast acquisition which can introduce greater variability improving with averaged acquisition. Last, as mentioned before, the location of AR severity assessment must be obtained at the sinotubular junction for greater accuracy and reproducibility.[18]

MULTIDETECTOR CARDIAC CT. Cardiac CT is not a first-line imaging tool for assessment of AR severity as it cannot provide a direct measurement of flow. However, with electrocardiogram-synchronized acquisition either covering the entire cardiac cycle (retrospective) or just diastolic phases (prospective), cardiac CT does allow for assessment of aortic valve/root morphology and structure and can be used to help quantify severity by means of geometric measurements of the regurgitant orifice area (ROA).

ROA estimation by CT can be useful in selected patients with difficult echocardiographic images; however, it tends to be overestimated in comparison to proximal isovelocity surface area-derived ROA by TEE. The few published CT studies that suggest ROA cut-off values for the diagnosis of moderate and severe AR (using TTE as the reference standard) vary widely in their results: 25 mm^2 and 75 mm^2 by Alkadhi et al[25], 27 mm^2 and 47 mm^2 by Jeon et al[26], and 25 mm^2 and 37 mm^2 by Goffinet et al.[14] This is perhaps due to the fact that the proximal isovelocity surface area method estimates the area of the vena contracta width which tends to be smaller than the geometric regurgitant area.[14] However, ROA quantification of AR severity using CT planimetry correlates well with CMR assessment of AR. Ko et al[27] found that ROAs of 15 mm^2 and 23 mm^2 allow good discrimination between mild, moderate, and severe AR by CMR.

There are notable limitations in the CT assessment of AR severity; therefore, this technique is used less often to quantify AR. For example, in cases of AR with eccentric jets and/or commissural insufficiency, a higher degree of AR may not be accompanied by an increased ROA. ROA measurement can also be difficult in patients with cusp prolapse and/or calcification at the cusp margins, which cause significant artifacts. However, this has not been found to impair

JACC VOL. 82, NO. 20, 2023
NOVEMBER 14, 2023:1953–1966

FIGURE 2 CMR Assessment in Patients With Chronic AR

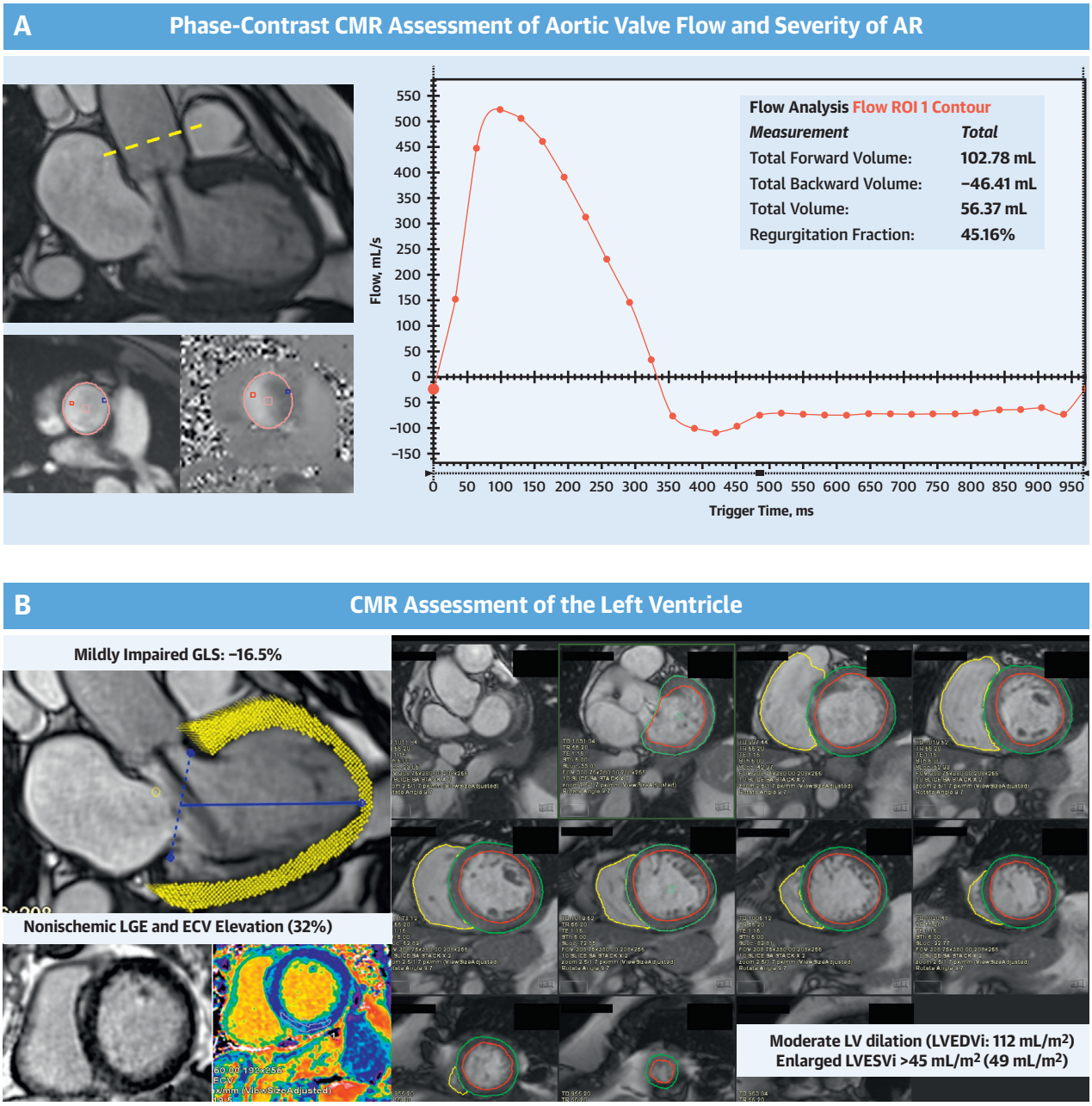

(A) Phase-contrast cardiac magnetic resonance (CMR) image acquisition is performed to measure forward stroke volume, regurgitant volume, and regurgitant fraction to measure AR severity. It is measured in a plane perpendicular to the aortic root at the level of the sinotubular junction (yellow dashed line). A flow-time curve is generated by integration of velocity and area data at each phase in the cardiac cycle. In this example, the holodiastolic flow reversal and high aortic RF are consistent with severe AR. (B) CMR evaluation of the LV response to chronic AR includes systolic function assessment by LV ejection fraction and strain, volumetric assessment of LV dilation, and myocardial fibrosis estimated by late gadolinium enhancement (LGE) and extracellular volume (ECV) measurement. GLS = global longitudinal strain; LVEDVi = left ventricle end-diastolic volume index; LVESVi = left ventricular end-systolic volume index; other abbreviations as in Figure 1.

the correlation between CMR grade of AR and CT ROA assessment.[27]

Importantly, diseases of the aorta often accompany aortic valve disorders, and cardiac CT plays a key role in the assessment of the aortic root and ascending aorta. Cardiac CT clearly defines the aortic wall, and multiplanar reconstruction can be used to create aortic images in a plane perpendicular to the aortic lumen allowing correction of shape distortions from aortic tortuosity. Aortic root and ascending aorta dimension measurements are highly reproducible across studies.[28] Indexing of aortic size to height and body size should also be considered as this has been shown to improve risk stratification compared to unindexed aortic dimensions.[29-31]

The thresholds for significant AR vary depending on the imaging modality used. **Table 2** summarizes the key factors that can be evaluated by echocardiography and CMR when assessing AR severity. Limited echocardiographic imaging windows or eccentric regurgitation jets can cause underestimation of AR severity by echocardiography. When significant AR is still suspected based on clinical symptomatology and/or LV parameters, further evaluation should be pursued with CMR.

TABLE 2 Classification of Significant AR by Echocardiography and CMR Imaging: Qualitative and Quantitative Parameters

	Echocardiography[13]	CMR
Jet width	≥65% of LVOT (2D color Doppler)	–
Vena contracta width, mm	>6.0 (2D color Doppler)	–
Vena contracta area, cm^2	>0.4 (3D color Doppler)	–
Pressure halftime, ms	<200 ms	–
Diastolic retrograde flow in aorta	Holodiastolic, end-diastolic flow V_{max} >20 cm/s	Holodiastolic, end-diastolic flow V_{max} > 20 cm/s[17]
Regurgitant volume, mL	≥60	–
Regurgitant fraction, %	≥50	>30 to 40[16-18,20-23]
EROA, cm^2	≥0.3	–

2D = 2-dimensional; 3D = 3-dimensional; CMR = cardiac magnetic resonance; EROA = estimated regurgitant orifice area; LVOT = left ventricular outflow tract; V_{max} = maximum velocity.

DIAGNOSTIC EVALUATION OF LV RESPONSE AND REMODELING

AR severity and clinical outcomes both strongly correlate with LV dilation.[32,33] Assessment of LV dilation aids in the risk stratification of patients with significant AR. However, there are multiple causes of LV dilation or dysfunction aside from AR; therefore, assuring that LV remodeling is a result of AR rather than an alternative process before deciding if a patient requires intervention is imperative.

ECHOCARDIOGRAPHY. The TTE examination begins with measurement of left ventricular internal end-diastolic dimension (LVEDD) and end-systolic dimension (LVESD), left ventricular end-diastolic and end-systolic volumes (LVEDV and LVESV, respectively) and LVEF. Data demonstrating the prognostic value of LV internal dimensions have withstood the test of time despite their intrinsic limitations, and are the foundation for the LV chamber size cut-off values used in both American College of Cardiology/American Heart Association and European Society of Cardiology/European Association of Cardio-Thoracic Surgery practice guideline for patients with valvular heart disease for determination of the timing of surgical intervention.[8,34-36] LVEDD and LVESD are reproducible, relatively easy to perform, and strong predictors of survival. Increased LVESD, in particular, reflects not only severity of LV dilation but also LV systolic dysfunction. Hence, LVESD prognostic performance has exceeded that of LVEDD. Several studies have shown that a left ventricular end-systolic dimension index (LVESDi) ≥25 mm/m^2 alone is associated with excess mortality;[37,38] this has provided the basis for the current guideline recommendation for surgical intervention at this threshold.[8,9,37,38] However, more recent studies suggest that a cut-off value of 25 mm/m^2 may be too conservative, and there may be a higher risk of adverse outcomes earlier, perhaps once LVESDi is ≥20 mm/m^2. Mentias et al[39] suggested increased risk when LVESDi reached >20 mm/m^2 and de Meester et al[40] showed excess mortality once LVESDi was ≥25 mm/m^2 compared to <25 mm/m^2. Yang et al[41] similarly showed an increased mortality when LVESDi is 20 to 25 mm/m^2 (HR: 1.53; 95% CI: 1.01-2.31), and yet an even greater mortality risk at ≥25 mm/m^2 (HR: 2.23; 95% CI: 1.32-3.77). Although these findings have been confirmed in another recent study in which LVESDi in the range of 20 to 25 mm/m^2 was suggested as a threshold for surgical referral in patients with asymptomatic severe AR and preserved LVEF, this evidence is based on retrospective, single-center observational studies.[42] Therefore, further investigation is needed before becoming standard of care.

On the other hand, LVEDD and LVESD are linear dimensions and may underestimate LV size in the presence of asymmetric enlargement. Measurement can sometimes be difficult in the presence of

JACC VOL. 82, NO. 20, 2023
NOVEMBER 14, 2023:1953-1966

hypertrophy of the basal septum. Additionally, early data supporting the use of these linear parameters were based on M-mode methodology, whereas such measurements are currently performed with 2D techniques.[34-36]

LV volumes are ideally suited to provide a more comprehensive assessment of global LV dilation and have been shown to reflect the hemodynamic burden on the LV in patients with AR. Recently, a threshold LVESVi ≥45 mL/m^2 was shown to be significantly associated with increased mortality risk in asymptomatic patients with chronic moderately severe to severe AR. Additionally, LVESVi performed equally well to LVESDi in discriminating excess mortality in chronic AR patients.[42]

However, LV volumes are less reproducible in the setting of poor image quality and in cases of image foreshortening.[43] Therefore, care must be taken to obtain apical images that are not foreshortened to ensure accurate and reproducible LV volumes assessment. The use of echocardiography enhancing agents has been shown to improve the accuracy of LV volumes assessment and should be used in patients with suboptimal image quality.[44] 3D TTE can potentially overcome the drawbacks of 2D volumes because geometric assumptions are required for measurement of 2D LV volumes and LVEF. LV volumes by 3D TTE have been shown to be closer than 2D TTE to volume measurements assessed by CMR.[45] The accuracy of 3D TTE measurements is also highly dependent on image quality; therefore, 3D imaging is not useful nor feasible in every patient. Additionally, there is a paucity of prognostic data for 3D TTE volumes in the assessment of outcomes in patients with AR.

Although analysis of LV volumes, if feasible, is associated with outcomes, identifying LV dysfunction early in the disease process remains challenging. Ideally, more sensitive parameters of LV dysfunction are needed. LV deformation imaging has recently been shown to be highly reproducible and have prognostic value in a variety of disease states. Olsen et al[46] showed that reduced myocardial systolic strain, systolic strain rate, and early diastolic strain rate measured using speckle tracking echocardiography are associated with disease progression during conservative management and with impaired outcomes after surgery. Global longitudinal strain (GLS) is currently the most widely used echocardiographic technique to assess myocardial deformation. Software to measure GLS quickly and accurately is currently available on most modern echocardiographic imaging systems. Olsen et al[46] suggested that the best cut-off value discriminating between patients with disease progression and stable disease during conservative management is a GLS value of −18% (area under the curve [AUC]: 0.72; sensitivity, 88%; specificity, 60%), and the best cut-off for predicting surgical outcomes is a GLS value of −14% (AUC: 0.77; sensitivity, 82%; specificity, 72%). In another study by Alashi et al,[47] in patients with chronic AR and preserved ejection fraction (EF), an LV-GLS value worse than −19.5% was associated with a significantly increased 5-year risk of death. Furthermore, patients who continue to show impaired LV-GLS post aortic valve replacement (worse than −19%) or worsening of LV-GLS by >5% points post aortic valve replacement have significantly higher long-term mortality.[48] Yang et al[49] found that LV-GLS worse than −15% alone has a 2.6-fold risk for death (95% CI: 1.54-4.23); furthermore, the combination of LV-GLS worse than −15% and LVESVi >45 mL/m^2 had a 3.96-fold risk of death (95% CI: 1.94-8.03). Thus, the addition of LV-GLS aids in the management of patients with chronic AR.[48,49] Although agreement on the precise cut-off value for GLS that would prompt surgical intervention remains to be defined, a depressed GLS value in the range of −15% to −19% is useful, particularly in patients with LV dilation.

A marked limitation of LV-GLS utility, especially in chronic AR, is the degree to which it can be affected by loading conditions. Myocardial work, LV global work index, and LV global constructive work are load-independent parameters that have been introduced as alternative measures to assess myocardial function in chronic AR patients with preserved LVEF. Both LV global work index and LV global constructive work have been shown retrospectively to correlate with markers of AR severity and improve after surgical aortic valve replacement. Additionally, postoperative impairment in LV global work index is associated with adverse LV remodeling.[50] However, further studies are needed to establish the prognostic implications of these myocardial work parameters.

CMR. CMR has great utility in assessing the LV response to chronic AR. This assessment includes systolic function assessment by LVEF and strain imaging, volumetric assessment of LV dilation as well as myocardial fibrosis assessment by late gadolinium enhancement and extracellular volume (ECV) (**Figure 2B**).

CMR is the gold standard for LV volumetric assessment. CMR LV volume measurements are precise and reproducible when performed by experienced centers.[51] Capron et al[33] compared the discriminatory ability of echocardiographic and CMR linear dimensions and volume assessment in predicting AR severity and showed that left ventricular end-diastolic volume index (LVEDVi) assessment by CMR has the best discriminatory ability with an AUC of 0.91. LV volumes are consistently underestimated on echocardiography compared to CMR; this is likely due to difficultly defining a clear LV endocardial border on echocardiography.[15,45,52-55] As serial assessment of LV dilation is important in decision-making for asymptomatic patients with significant AR, if available, CMR can be the reference imaging method for monitoring LV dilation over time.

CMR volumetric assessment can be used as a threshold for early intervention and to predict reverse remodeling postintervention in AR patients. In asymptomatic AR patients, CMR-derived LVEDV assessment (LVEDV >246 mL, LVEDVi >129 mL/m^2), especially when combined with quantitative assessment of RF and RV, has good discriminatory ability for predicting development of symptoms or an indication for surgery (AUC: 0.88 and 0.86, respectively).[20] Seldrum et al[56] found that patients undergoing surgical aortic valve replacement with an LVEDVi >155 mL/m^2 were more likely to show poor reverse remodeling after aortic valve replacement (AUC: 0.90).

Hashimoto et al[21] reported that CMR LV volumes, but not echocardiographic linear dimensions or volumetric assessment, can also discriminate those asymptomatic/minimally symptomatic vs symptomatic AR. In asymptomatic patients in that study, LVESVi >45 mL/m^2 by CMR was associated with increased risk of cardiac events (death, heart failure, symptomatic progression to aortic valve replacement), with a threshold similar to that reported by Yang et al[42] using 2D echo assessment of LVESVi.[21] Additionally, highly accurate assessment of CMR-RV and CMR-RF provided additional prognostic value to this cohort.[21]

CMR can also assess the consequences of progressive volume and pressure overload by evaluation of myocardial fibrosis and strain. Chronic AR is associated with reactive fibrosis, and T1 mapping with CMR can quantify this process. Assessment of these cellular changes by CMR is highly predictive of clinical outcomes. Regional replacement fibrosis can be assessed with late gadolinium enhancement. Myocardial scar is independently associated with a 2.5-fold increased risk of mortality in chronic AR patients.[57] Diffuse interstitial fibrosis and extracellular matrix expansion, or ECV, can be assessed with T1 mapping techniques (scanner-dependent). ECV, computed from pre-post contrast CMR T1 time changes, correlates significantly with the magnitude of histological fibrosis, AR severity, and adverse clinical outcomes.[40,58] Senapati et al[58] found that an indexed ECV (ECV × indexed LV end-diastolic myocardial volume) cut-off ≥24 mL/m^2 was associated with either death or need for aortic valve replacement. However, indexed ECV is strongly dependent on LVEDV; therefore, the relationship of ECV to clinical outcomes is likely not independent.

LV strain assessment by CMR-feature tracking is possible with routine cine imaging, and, similar to echocardiography, is a promising technology associated with outcomes. Preliminary data from Fernández-Golfin et al[59] in patients with chronic AR shows an association of CMR-GLS with AR severity. In addition, AR patients with abnormal GLS (worse than −16%), abnormal global circumferential strain (<17%) or abnormal global radial strain (<32%) showed a significantly higher rate of clinical events, including mortality. CMR strain imaging as a predictor of clinical outcomes will require larger prospective cohort studies to investigate if this relationship remains independent of LV volume changes.

MULTIDETECTOR CARDIAC CT. Functional cardiac CT angiography (CCTA) is an excellent tool for assessment of LV volumes and LV systolic function providing accurate measurements when compared to CMR and TTE.[60,61] Using CMR as the reference standard, CCTA evaluation of LV volumes has been shown to correlate well with CMR (end-diastolic volume r = 0.97, end-systolic volume r = 0.97).[55,62,63] If automated software is used for quantification of LV volumes, it is important to note whether papillary muscles are included or excluded from LV mass as this can significantly change the measured LV volumes.[64]

A few limitations of CCTA include the need for adequate intravenous contrast (which can worsen renal function), radiation exposure, and the necessity for a regular and slow heart rate at the time of acquisition. These factors are essential in obtaining adequate imaging for analysis but may not always be feasible depending on patient specific factors. Additionally, assessment of chamber volumes requires that CT acquisition covers the entire cardiac cycle. One must be mindful of the limitations of CT in patients with atrial fibrillation and increased heart rate

JACC VOL. 82, NO. 20, 2023
NOVEMBER 14, 2023:1953–1966

FIGURE 3 The Role of LV Response in Determining the Timing of Intervention

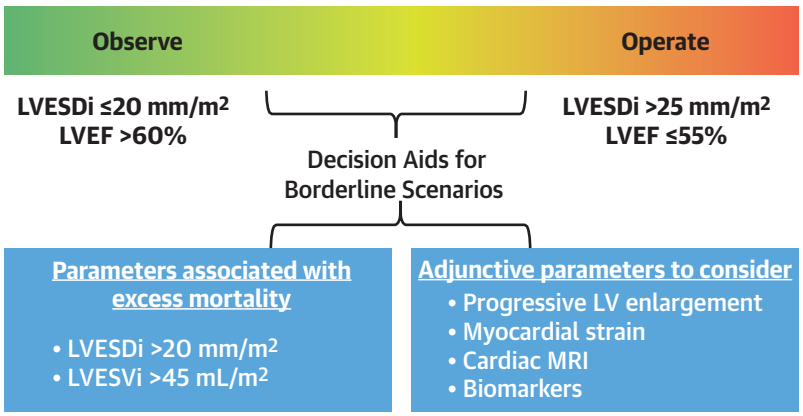

There are accumulating data indicating an excess mortality and other adverse cardiac events at thresholds of LVESDi >20 mm/m^2, LVESVi >45 mL/m^2, and ejection fraction <60% in patients with significant AR. These factors in addition to myocardial strain imaging and plasma biomarkers can be considered in borderline scenarios about whether to observe or pursue an intervention. LVEF = left ventricular ejection fraction; MRI = magnetic resonance imaging; other abbreviations as in Figures 1 and 2.

variability, which are specific for the CT scanner system used. Although CT imaging acquired with CT systems with limited detector coverage may experience step artifact, volume CT scanners with whole heart acquisition are typically artifact free but may not cover a representative RR-interval, ultimately leading to underestimation of the LVEDV. Electrocardiogram tracing recorded by the CT scanner should be reviewed and included into the interpretation of the quantitative measures.

INTEGRATIVE IMAGING APPROACH IN A PATIENT WITH SIGNIFICANT CHRONIC AR

The decision of whether a patient with AR requires intervention is dependent on the assessment of clinical symptoms, AR severity, and LV remodeling.

The evaluation of symptoms is critically important; however, it can be challenging because patients usually chronically adapt to the hemodynamic burden of AR slowly over time and may not be aware of any physical limitations. Exercise treadmill stress testing may serve as an aid in the assessment of exercise tolerance.

Assessment of AR severity requires the correlation of the physical examination and the initial TTE. If there is discordance between the clinical data and TTE (eg, loud diastolic murmur and wide pulse pressure, but TTE parameters not consistent with severe AR), then further imaging is necessary. There may also be internal discrepancies in the TTE itself, such as indications of severe AR by proximal isovelocity surface area or volumetric analysis but normal LV outflow velocity or absence of LV dilation. Eccentric regurgitation jets are a common cause for imaging discrepancies. TEE or CMR can be useful in resolving these discrepancies. The thresholds of severity of AR vary depending on the imaging modality used, and lower thresholds of regurgitant fraction by CMR compared to TTE have been shown by several groups to be associated with progression of symptoms, need for aortic valve replacement, and cardiovascular outcomes. Aortic root angiography can also provide semiquantitative assessment of AR severity.[65]

Beyond determining severity of valvular regurgitation, accurate serial assessment of the extent of LV remodeling plays a central role in determining the optimal timing of surgical intervention. Measurements of both LV size and systolic function, and changes in these measurements over time, are key as they are significantly associated with outcomes in patients with significant AR. TTE is the initial imaging modality for both the initial assessment of LV size and function. However, if there is poor endocardial definition on TTE or if there are “borderline” parameters, CMR or CT should be used to provide a more accurate and reproducible assessment of LV size and function.

LV remodeling in response to AR varies with age and sex. Research suggests that older and/or female patients have a blunted LV response in comparison to younger and/or male patients.[66-68] This elucidates

why fewer women are referred for AV intervention based on LV parameters and also potentially contributes to the inferior observed outcomes.[67,69] Thus, these factors are important to consider when evaluating the LV. Sex and age-based thresholds for intervention remain fertile ground for future research. It is also important to determine whether LV enlargement and/or dysfunction is due to severity of AR or another etiology.

As noted previously, there are accumulating data for severe AR indicating an excess mortality and other adverse cardiac events at thresholds of LVESDi >20 mm/m^2, LVESVi >45 mL/m^2, and LVEF <60%.[41,42] Additional measures of LV function including LV-GLS, and the degree/extent of myocardial fibrosis may also help in predicting the onset of myocardial dysfunction. Thus, the suggested method to determine the treatment course of the patient with severe AR is as follows: 1) If symptoms or limited exercise tolerance, then operate; 2) If current guideline thresholds are reached (LVESDi >25 mm/m^2 or LVEF <55%), then operate; 3) If the patient is below lower limits of adverse outcomes (LVESDi <20 mm/m^2 and LVEF >60%), then observe; and 4) If the patient is in the intermediate range (LVESDi 20 mm/m^2 to 25 mm/m^2, LVEF 55% to 60%), then incorporate other factors (**Figure 3**, **Table 3**).

Adjunctive parameters to consider include LV volumes (>45 mL/m^2), LV-GLS, severity of RV and RF, plasma biomarkers, and the degree and extent of myocardial fibrosis. Importantly, progressive changes in LV size and function should be considered. Because of the variability of any single measurement of either LV size or function by echocardiography, measurements from at least 3 studies should be used, or if available, tracked by CMR given its superior reproducibility. B-type natriuretic peptide (BNP) is the most studied plasma biomarker that has prognostic importance. Elevated or progressively increasing BNP can indicate advancing valve disease and predicts poor clinical outcomes.[38,70,71] In asymptomatic, severe AR patients with normal LV size and function, one study showed a BNP value ≥130 pg/mL to be associated with adverse outcomes.[38] Finally, the needs and preferences of the individual patient should be taken into consideration using a shared decision-making process.

TABLE 3 Emerging Ventricular Parameters Associated With Adverse Outcomes by Echocardiography and CMR Imaging[a]

	Echocardiography	CMR
LVEDV	–	>246 mL or 129 mL/m^2 [20]
LVESVi	>45 mL/m^2 [42,49]	≥43-45 mL/m^2 [21,72]
LVESDi	20-25 mm/m^2 [39-42]	
GLS, %	Worse than −15 to −19[46-49]	Worse than 16[59]
Indexed extracellular volume, mL/m^2	–	≥24[58]

[a]Emerging data based on nonrandomized, retrospective data.

GLS = global longitudinal strain; LVEDV = left ventricular end-diastolic volume; LVESDi = left ventricular end-systolic dimension index; LVESVi = left ventricular end-systolic volume index; other abbreviation as in **Table 2**.

CONCLUSIONS

The diagnosis of AR severity and the imaging criteria used for intervention for AR are less well established than those used for aortic stenosis. All available information, both clinical (ie, vital signs, physical examination, and symptoms) and imaging, must be integrated into determining whether AR is significant (**Central Illustration**). Although echocardiography is the first-line imaging technique used in chronic significant AR, CMR is useful to assess AR severity and LV remodeling when echocardiography data are discrepant.

Assessment of LV volumes, myocardial strain, and myocardial fibrosis may be helpful for patients who are in the indeterminate range for management based on current guidelines (LVESDi 20 mm/m^2 to 25 mm/m^2, LVEF 55% to 60%). Based on the current data available, we cannot establish causality but only associations between these thresholds (LVEF <60%, GLS worse than −15 to −19, LVESDi >20 mm/m^2, LVESVi >45 mL/m^2) and worse prognosis; therefore, no single imaging-based early threshold is absolute.

Intervening in patients with severe AR before the onset of LV dysfunction may prevent irreversible remodeling that occurs with long-standing pressure and volume overload. Adjunctive imaging parameters hold promise in helping guide the timing of surgical intervention and may be incorporated into decision-making as more robust data becomes available. This will become particularly important in the future with refinement of surgical aortic valve repair techniques, reduction in operative risks, and the likely emergence of AR-specific transcatheter therapies.

FUNDING SUPPORT AND AUTHOR DISCLOSURES

Dr Ranard has received institutional funding to Columbia University from Boston Scientific. Dr Bax has received speaker bureau fees from Abbott and Edwards Lifesciences. Dr Delgado has received

JACC VOL. 82, NO. 20, 2023
NOVEMBER 14, 2023:1953–1966

CENTRAL ILLUSTRATION Summary of the Assessment and Therapy Decisions for Chronic Aortic Regurgitation

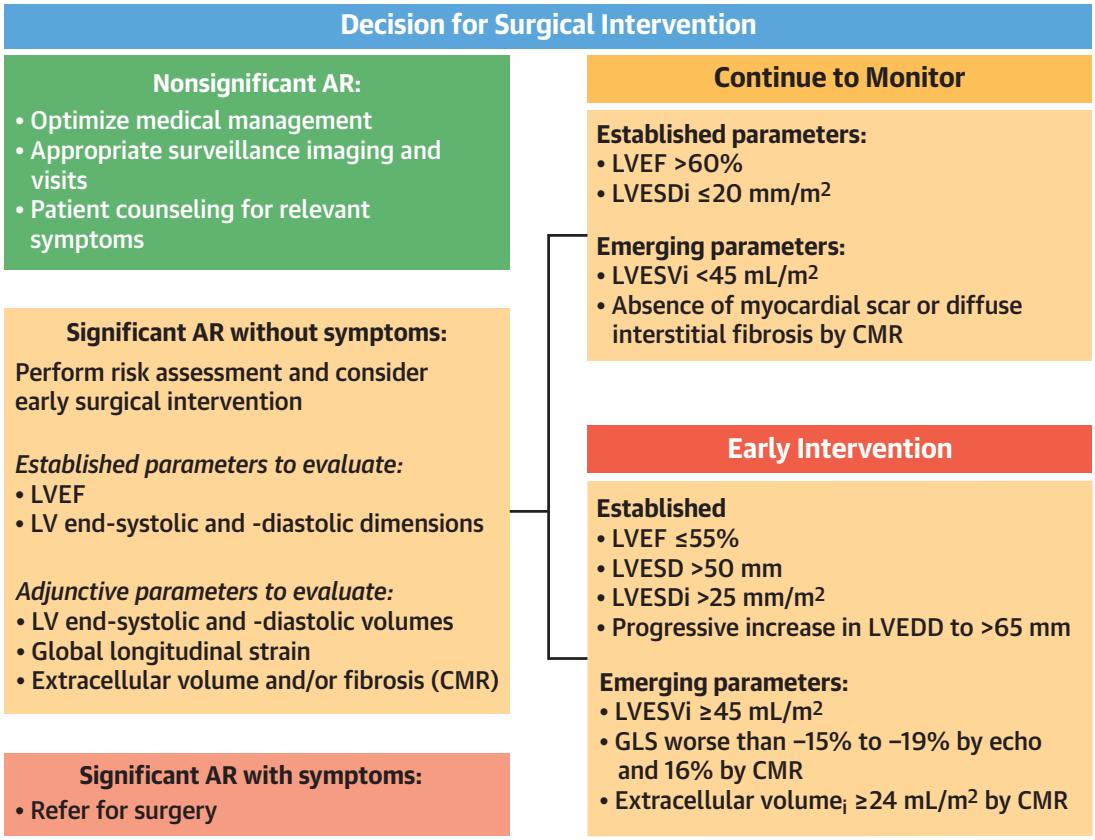

Ranard LS, et al. J Am Coll Cardiol. 2023;82(20):1953–1966.

The assessment of a patient with aortic regurgitation (AR) is primarily composed of clinical examination and echocardiography. However, in patients with borderline metrics or if precise volumetric assessment of chamber sizes is needed, cardiac magnetic resonance (CMR) imaging may be useful. The figure outlines the management decisions based on AR severity and symptomatology along with established and emerging parameters obtained from imaging studies. GLS = global longitudinal strain; LV = left ventricular; LVEDD = left ventricular internal end-diastolic dimension; LVEF = left ventricular ejection fraction; LVESD = left ventricular end-systolic dimension; LVESDi = left ventricular end-systolic dimension index; LVESVi = left ventricular end-systolic volume index.

speaker fees from Abbott Vascular, Edwards Lifesciences, GE Healthcare, Medtronic, Novartis, and Philips; and has received consulting fees from Edwards Lifesciences and Novo Nordisk. Dr Leipsic has received institutional CT core lab contracts with Edwards Lifesciences, Abbott, Boston Scientific, Medtronic, and PI Cardia. Dr Lang is on the Speakers Bureau and has received grants from Philips Medical Systems. Dr Vahl has received institutional funding to Columbia University Irving Medical Center from Boston Scientific, Edwards Lifesciences, JenaValve, Medtronic, and Siemens Healthineers; and has personally received consulting fees from 4C Medical, Abbott Vascular, and Boston Scientific. Dr Leon has received institutional clinical research grants from Abbott, Boston Scientific, Edwards Lifesciences, Medtronic, and JenaValve. Dr Rigolin has stock ownership in Edwards Lifesciences. All other authors have reported that they have no relationships relevant to the contents of this paper to disclose.

ADDRESS FOR CORRESPONDENCE: Dr Rigolin, Division of Cardiology, Northwestern University Feinberg School of Medicine, Northwestern Memorial Hospital, 675 North St. Clair Street, Suite 19-100, Chicago, Illinois 60611, USA. E-mail: vrigolin@nm.org.

REFERENCES

1. d'Arcy JL, Coffey S, Loudon MA, et al. Large-scale community echocardiographic screening reveals a major burden of undiagnosed valvular heart disease in older people: the oxvalve population cohort study. *Eur Heart J*. 2016;37:3515–3522.

2. He S, Deng H, Jiang J, et al. The evolving epidemiology of elderly with degenerative valvular heart disease: the Guangzhou (China) heart study. *Biomed Res Int*. 2021:9982569.

3. Yang L-T, Michelena HI, Maleszewski JJ, Schaff HV, Pellikka PA. Contemporary etiologies, mechanisms, and surgical approaches in pure native aortic regurgitation. *Mayo Clin Proc*. 2019;94:1158–1170.

4. Roberts WC, Ko JM, Moore TR, Jones WHI. Causes of pure aortic regurgitation in patients having isolated aortic valve replacement at a single us tertiary hospital (1993 to 2005). *Circulation*. 2006;114:422–429.

5. Yang L-T, Benfari G, Eleid M, et al. Contemporary differences between bicuspid and tricuspid aortic valve in chronic aortic regurgitation. *Heart*. 2021;107:916–924.

6. Braverman AC, Güven H, Beardslee MA, et al. The bicuspid aortic valve. *Curr Probl Cardiol*. 2005;30:470–522.

7. Bekeredjian R, Grayburn PA. Valvular heart disease: aortic regurgitation. *Circulation*. 2005;112:125–134.

8. Otto CM, Nishimura RA, Bonow RO, et al. 2020 ACC/AHA guideline for the management of patients with valvular heart disease: a report of the American College of Cardiology/American Heart Association joint committee on clinical practice guidelines. *J Am Coll Cardiol*. 2021;77:e25–e197.

9. Vahanian A, Beyersdorf F, Praz F, et al. 2021 ESC/EACTS guidelines for the management of valvular heart disease: developed by the task force for the management of valvular heart disease of the European Society of Cardiology (ESC) and the European Association for Cardio-Thoracic Surgery (EACTS). *Eur J Cardiothorac Surg*. 2021;60:727–800.

10. Mack MJ, Leon MB, Wu C, Zuckerman B. Heart Valve Collaboratory Scientific Council. The Heart Valve Collaboratory: a disruptive model in the management of valvular heart disease. *J Am Coll Cardiol*. 2022;79:192–196.

11. Michelena HI, Enriquez-Sarano M. Corrigan's pulse and Quincke's pulse. *N Engl J Med*. 2018;379:e9.

12. Yang L-T, Pellikka PA, Enriquez-Sarano M, et al. Diastolic blood pressure and heart rate are independently associated with mortality in chronic aortic regurgitation. *J Am Coll Cardiol*. 2020;75:29–39.

13. Zoghbi WA, Adams D, Bonow RO, et al. Recommendations for noninvasive evaluation of native valvular regurgitation: a report from the American Society of Echocardiography developed in collaboration with the Society for Cardiovascular Magnetic Resonance. *J Am Soc Echocardiogr*. 2017;30:303–371.

14. Goffinet C, Kersten V, Pouleur A-C, et al. Comprehensive assessment of the severity and mechanism of aortic regurgitation using multidetector CT and MR. *Eur Radiol*. 2010;20:326–336.

15. Cawley PJ, Hamilton-Craig C, Owens DS, et al. Prospective comparison of valve regurgitation quantitation by cardiac magnetic resonance imaging and transthoracic echocardiography. *Circ Cardiovasc Imaging*. 2013;6:48–57.

16. Gelfand EV, Hughes S, Hauser TH, et al. Severity of mitral and aortic regurgitation as assessed by cardiovascular magnetic resonance: optimizing correlation with Doppler echocardiography. *J Cardiovasc Magn*. 2006;8:503–507.

17. Kammerlander AA, Wiesinger M, Duca F, et al. Diagnostic and prognostic utility of cardiac magnetic resonance imaging in aortic regurgitation. *J Am Coll Cardiol Img*. 2019;12:1474–1483.

18. Gabriel RS, Renapurkar R, Bolen MA, et al. Comparison of severity of aortic regurgitation by cardiovascular magnetic resonance versus transthoracic echocardiography. *Am J Cardiol*. 2011;108:1014–1020.

19. Ewe S, Delgado V, van der Geest R, et al. Accuracy of three-dimensional echocardiography for quantification of aortic regurgitation and validation by three-dimensional three-directional velocity-encoded magnetic resonance imaging. *Am J Cardiol*. 2013;112:560–566.

20. Myerson SG, d'Arcy J, Mohiaddin R, et al. Aortic regurgitation quantification using cardiovascular magnetic resonance: association with clinical outcome. *Circulation*. 2012;126:1452–1460.

21. Hashimoto G, Enriquez-Sarano M, Stanberry LI, et al. Association of left ventricular remodeling assessment by cardiac magnetic resonance with outcomes in patients with chronic aortic regurgitation. *JAMA Cardiol*. 2022;7:924–933.

22. Faber M, Sonne C, Rosner S, et al. Predicting the need of aortic valve surgery in patients with chronic aortic regurgitation: a comparison between cardiovascular magnetic resonance imaging and transthoracic echocardiography. *Int J Cardiovasc Imaging*. 2021;37:2993–3001.

23. Vejpongsa P, Xu J, Quinones MA, Shah DJ, Zoghbi WA. Differences in cardiac remodeling in left-sided valvular regurgitation: implications for optimal definition of significant aortic regurgitation. *J Am Coll Cardiol Img*. 2022;15:1730–1741.

24. Gatehouse PD, Rolf MP, Graves MJ, et al. Flow measurement by cardiovascular magnetic resonance: a multi-centre multi-vendor study of background phase offset errors that can compromise the accuracy of derived regurgitant or shunt flow measurements. *J Cardiovasc Magn*. 2010;12:1–8.

25. Alkadhi H, Desbiolles L, Husmann L, et al. Aortic regurgitation: assessment with 64-section CT. *Radiology*. 2007;245:111–121.

26. Jeon MH, Choe YH, Cho SJ, et al. Planimetric measurement of the regurgitant orifice area using multidetector CT for aortic regurgitation: a comparison with the use of echocardiography. *Korean J Radiol*. 2010;11:169–177.

27. Ko SM, Park JH, Shin JK, Kim JS. Assessment of the regurgitant orifice area in aortic regurgitation with dual-source CT: comparison with cardiovascular magnetic resonance. *J Cardiovasc Comput Tomogr*. 2015;9:345–353.

28. Goldstein SA, Evangelista A, Abbara S, et al. Multimodality imaging of diseases of the thoracic aorta in adults: from the American Society of Echocardiography and the European Association of Cardiovascular Imaging: endorsed by the Society of Cardiovascular Computed Tomography and Society for Cardiovascular Magnetic Resonance. *J Am Soc Echocardiogr*. 2015;28:119–182.

29. Masri A, Svensson LG, Griffin BP, Desai MY. Contemporary natural history of bicuspid aortic valve disease: a systematic review. *Heart*. 2017;103:1323–1330.

30. Masri A, Kalahasti V, Svensson LG, et al. Aortic cross-sectional area/height ratio and outcomes in patients with a trileaflet aortic valve and a dilated aorta. *Circulation*. 2016;134:1724–1737.

31. Members WC, Isselbacher EM, Preventza O, et al. 2022 ACC/AHA guideline for the diagnosis and management of aortic disease: a report of the American Heart Association/American College of Cardiology joint committee on clinical practice guidelines. *J Am Coll Cardiol*. 2022;80:e223–e393.

32. Uretsky S, Supariwala A, Nidadovolu P, et al. Quantification of left ventricular remodeling in response to isolated aortic or mitral regurgitation. *J Cardiovasc Magn*. 2010;12:1–7.

33. Capron T, Cautela J, Scemama U, et al. Cardiac magnetic resonance assessment of left ventricular dilatation in chronic severe left-sided regurgitations: comparison with standard echocardiography. *Diagn Interv Imaging*. 2020;101:657–665.

34. Henry WL, Bonow RO, Borer JS, et al. Observations on the optimum time for operative intervention for aortic regurgitation. I. Evaluation of the results of aortic valve replacement in symptomatic patients. *Circulation*. 1980;61:471–483.

35. Henry WL, Bonow RO, Rosing DR, Epstein SE. Observations on the optimum time for operative intervention for aortic regurgitation. II. Serial echocardiographic evaluation of asymptomatic patients. *Circulation*. 1980;61:484–492.

36. Bonow RO, Lakatos E, Maron BJ, Epstein SE. Serial long-term assessment of the natural history of asymptomatic patients with chronic aortic regurgitation and normal left ventricular systolic function. *Circulation*. 1991;84:1625–1635.

37. Dujardin KS, Enriquez-Sarano M, Schaff HV, et al. Mortality and morbidity of aortic regurgitation in clinical practice: a long-term follow-up study. *Circulation*. 1999;99:1851–1857.

38. Pizarro R, Bazzino OO, Oberti PF, et al. Prospective validation of the prognostic usefulness of B-type natriuretic peptide in asymptomatic patients with chronic severe aortic regurgitation. *J Am Coll Cardiol*. 2011;58:1705–1714.

39. Mentias A, Feng K, Alashi A, et al. Long-term outcomes in patients with aortic regurgitation and preserved left ventricular ejection fraction. *J Am Coll Cardiol*. 2016;68:2144–2153.

40. De Meester C, Gerber BL, Vancraeynest D, et al. Do guideline-based indications result in an outcome penalty for patients with severe aortic regurgitation? *J Am Coll Cardiol Img*. 2019;12:2126–2138.

41. Yang L-T, Michelena HI, Scott CG, et al. Outcomes in chronic hemodynamically significant aortic regurgitation and limitations of current guidelines. *J Am Coll Cardiol*. 2019;73:1741–1752.

42. Yang L-T, Anand V, Zambito EI, et al. Association of echocardiographic left ventricular end-systolic volume and volume-derived ejection fraction with outcome in asymptomatic chronic aortic regurgitation. *JAMA Cardiol*. 2021;6:189–198.

43. Anand V, Yang L, Luis SA, et al. Association of left ventricular volume in predicting clinical outcomes in patients with aortic regurgitation. *J Am Soc Echocardiogr*. 2021;34:352–359.

44. Thomson HL, Basmadjian A-J, Rainbird AJ, et al. Contrast echocardiography improves the accuracy and reproducibility of left ventricular remodeling measurements: a prospective, randomly assigned, blinded study. *J Am Coll Cardiol*. 2001;38:867–875.

45. Mor-Avi V, Jenkins C, Kühl HP, et al. Real-time 3-dimensional echocardiographic quantification of left ventricular volumes: multicenter study for validation with magnetic resonance imaging and investigation of sources of error. *J Am Coll Cardiol Img*. 2008;1:413–423.

46. Olsen NT, Sogaard P, Larsson HB, et al. Speckle-tracking echocardiography for predicting outcome in chronic aortic regurgitation during conservative management and after surgery. *J Am Coll Cardiol Img*. 2011;4:223–230.

47. Alashi A, Mentias A, Abdallah A, et al. Incremental prognostic utility of left ventricular global longitudinal strain in asymptomatic patients with significant chronic aortic regurgitation and preserved left ventricular ejection fraction. *J Am Coll Cardiol Img*. 2018;11:673–682.

48. Alashi A, Khullar T, Mentias A, et al. Long-term outcomes after aortic valve surgery in patients with asymptomatic chronic aortic regurgitation and preserved LVEF: impact of baseline and follow-up global longitudinal strain. *J Am Coll Cardiol Img*. 2020;13:12–21.

49. Yang L-T, Takeuchi M, Scott CG, et al. Automated global longitudinal strain exhibits a robust association with death in asymptomatic chronic aortic regurgitation. *J Am Soc Echocardiogr*. 2022;35:692–702.

50. Meucci MC, Butcher SC, Galloo X, et al. Noninvasive left ventricular myocardial work in patients with chronic aortic regurgitation and preserved left ventricular ejection fraction. *J Am Soc Echocardiogr*. 2022;35:703–711.

51. Grothues F, Smith GC, Moon JC, et al. Comparison of interstudy reproducibility of cardiovascular magnetic resonance with two-dimensional echocardiography in normal subjects and in patients with heart failure or left ventricular hypertrophy. *Am J Cardiol*. 2002;90:29–34.

52. Jacobs LD, Salgo IS, Goonewardena S, et al. Rapid online quantification of left ventricular volume from real-time three-dimensional echocardiographic data. *Eur Heart J*. 2006;27:460–468.

53. Sugeng L, Mor-Avi V, Weinert L, et al. Quantitative assessment of left ventricular size and function: side-by-side comparison of real-time three-dimensional echocardiography and computed tomography with magnetic resonance reference. *Circulation*. 2006;114:654–661.

54. Jenkins C, Leano R, Chan J, Marwick TH. Reconstructed versus real-time 3-dimensional echocardiography: comparison with magnetic resonance imaging. *J Am Soc Echocardiogr*. 2007;20:862–868.

55. Rigolli M, Anandabaskaran S, Christiansen JP, Whalley GA. Bias associated with left ventricular quantification by multimodality imaging: a systematic review and meta-analysis. *Open Heart*. 2016;3:e000388.

56. Seldrum S, de Meester C, Pierard S, et al. Assessment of left ventricular reverse remodeling by cardiac MRI in patients undergoing repair surgery for severe aortic or mitral regurgitation. *J Cardiothorac Vasc Anesth*. 2019;33:1901–1911.

57. Malahfji M, Senapati A, Tayal B, et al. Myocardial scar and mortality in chronic aortic regurgitation. *J Am Heart Assoc*. 2020;9:e018731.

58. Senapati A, Malahfji M, Debs D, et al. Regional replacement and diffuse interstitial fibrosis in aortic regurgitation: prognostic implications from cardiac magnetic resonance. *J Am Coll Cardiol Img*. 2021;14:2170–2182.

59. Fernández-Golfín C, Hinojar-Baydes R, González-Gómez A, et al. Prognostic implications of cardiac magnetic resonance feature tracking derived multidirectional strain in patients with chronic aortic regurgitation. *Eur Radiol*. 2021;31:5106–5115.

60. Asferg C, Usinger L, Kristensen TS, Abdulla J. Accuracy of multi-slice computed tomography for measurement of left ventricular ejection fraction compared with cardiac magnetic resonance imaging and two-dimensional transthoracic echocardiography: a systematic review and meta-analysis. *Eur J Radiol*. 2012;81:e757–e762.

61. Wai B, Thai W-e, Brown H, Truong QA. Novel phase-based noise reduction strategy for quantification of left ventricular function and mass assessment by cardiac CT: comparison with cardiac magnetic resonance. *Eur J Radiol*. 2013;82:e337–e341.

62. Raman SV, Shah M, McCarthy B, Garcia A, Ferketich AK. Multi-detector row cardiac computed tomography accurately quantifies right and left ventricular size and function compared with cardiac magnetic resonance. *Am Heart J*. 2006;151:736–744.

63. Bak SH, Ko SM, Jeon HJ, et al. Assessment of global left ventricular function with dual-source computed tomography in patients with valvular heart disease. *Acta Radiologica*. 2012;53:270–277.

64. Mao SS, Li D, Rosenthal DG, et al. Dual-standard reference values of left ventricular volumetric parameters by multidetector ct angiography. *J Cardiovasc Comput Tomogr*. 2013;7:234–240.

65. Linhart JW. Aortic regurgitation: clinical, hemodynamic, surgical, and angiographic correlations. *Ann Thorac Cardiovasc Surg*. 1971;11:27–37.

66. Tower-Rader A, Mathias IS, Obuchowski NA, et al. Sex-based differences in left ventricular remodeling in patients with chronic aortic regurgitation: a multi-modality study. *J Cardiovasc Magn*. 2022;24:1–13.

67. Kammerlander AA, Donà C, Nitsche C, et al. Sex differences in left ventricular remodeling and outcomes in chronic aortic regurgitation. *J Clin Med*. 2020;9:4100.

68. Akintoye E, Saijo Y, Braghieri L, et al. Impact of age and sex on left ventricular remodeling in patients with aortic regurgitation. *J Am Coll Cardiol*. 2023;81:1474–1487.

69. Klodas E, Enriquez-Sarano M, Tajik AJ, et al. Surgery for aortic regurgitation in women: contrasting indications and outcomes compared with men. *Circulation*. 1996;94:2472–2478.

70. Bergler-Klein J, Gyöngyösi M, Maurer G. The role of biomarkers in valvular heart disease: focus on natriuretic peptides. *Can J Cardiol*. 2014;30:1027–1034.

71. Weber M, Hausen M, Arnold R, et al. Diagnostic and prognostic value of N-terminal pro B-type natriuretic peptide (NT-proBNBP) in patients with chronic aortic regurgitation. *Int J Cardiol*. 2008;127:321–327.

72. Malahfji M, Crudo V, Kaolawanich Y, et al. Influence of cardiac remodeling on clinical outcomes in patients with aortic regurgitation. *J Am Coll Cardiol*. 2023;81:1885–1898.

KEY WORDS aortic regurgitation, cardiac imaging, valvular heart disease