

**Title:** First-in-human experience of a new generation transfemoral transcatheter aortic valve for the treatment of severe aortic regurgitation: the J-Valve transfemoral system.

**Authors:** Mark Hensey, MB, BCh, BAO; Dale J Murdoch, MBBS; Janarthanan Sathananthan, MBChB; Abdullah Alenezi, M.D; Gnalini Sathananthan, M.D; Robert Moss, MBBS; Philipp Blanke, M.D; Jonathon Leipsic, M.D; David A Wood, M.D; Anson Cheung, M.D; Jian Ye, M.D; John G Webb, M.D

**DOI:** 10.4244/EIJ-D-18-00935

**Citation:** Hensey M, Murdoch DJ, Sathananthan J, Alenezi A, Sathananthan G, Moss R, Blanke P, Leipsic J, Wood DA, Cheung A, Ye J, Webb JG. First-in-human experience of a new generation transfemoral transcatheter aortic valve for the treatment of severe aortic regurgitation: the J-Valve transfemoral system. *EuroIntervention* 2018; Jaa-485 2018, doi: 10.4244/EIJ-D-18-00935

**Manuscript submission date:** 20 September 2018

**Revisions received:** 30 October 2018

**Accepted date:** 16 November 2018

**Online publication date:** 20 November 2018

**Disclaimer:** This is a PDF file of a "Just accepted article". This PDF has been published online early without copy editing/typesetting as a service to the Journal's readership (having early access to this data). Copy editing/typesetting will commence shortly. Unforeseen errors may arise during the proofing process and as such Europa Digital & Publishing exercise their legal rights concerning these potential circumstances.

**First-in-human experience of a new generation transfemoral transcatheter aortic valve for the treatment of severe aortic regurgitation: the J-Valve transfemoral system**

Mark Hensey MB BCh BAO

Dale J Murdoch MBBS

Janarthanan Sathananthan MBChB

Abdullah Alenezi MD

Gnalini Sathananthan MD

Robert Moss MBBS

Philipp Blanke MD

Jonathon Leipsic MD

David A Wood MD

Anson Cheung MD

Jian Ye MD

John G Webb MD

Centre for Heart Valve Innovation, St Paul's Hospital, University of British Columbia, Vancouver, Canada

**Running title:**

First-in-human transfemoral J-Valve system

**Address for Correspondence:**

John Webb MD, St. Paul's Hospital, 1081 Burrard Street, Vancouver, BC, Canada V6Z 1Y6

Email: john.webb@vch.ca

Telephone: +16048068804

**Disclosures:**

Drs. Blanke, Leipsic and Wood, and Webb are consultants to and receive research support from Edwards Lifesciences. Dr Cheung is a consultant to Abbott

*Disclaimer : As a public service to our readership, this article -- peer reviewed by the Editors of EuroIntervention - has been published immediately upon acceptance as it was received. The content of this article is the sole responsibility of the authors, and not that of the journal*

Vascular, Medtronic and Neovasc. Dr Ye is a consultant to Edwards Lifesciences and JC Medical.

**Word count:** 1339

**Classifications:**

Aortic regurgitation

Femoral

TAVI

**Funding statement:**

No funding sources

**Abbreviations:**

TAVI – Transcatheter aortic valve implantation

AS – Aortic stenosis

TA – Transapical

AR –Aortic Regurgitation

TF – Transfemoral

NYHA –New York Heart Association

LV –Left ventricular

TEE - Transesophageal echocardiography

TTE – Transthoracic echocardiography

## Introduction

Transcatheter aortic valve implantation (TAVI) is now well established in the contemporary management of severe aortic stenosis (AS) with a multitude of valve designs available. The transapical (TA) J-Valve system (JC Medical Inc., Burlingame, California, USA) has previously been shown to be effective for the treatment of both **severe** AS and aortic regurgitation (AR) (1, 2).

The J-Valve transcatheter aortic valve consists of the valve and three u-shaped 'anchor rings' (Figure 1A) **and is deployed in a two-step process. First** the anchor rings are opened above the native valve and are retracted (TA) or advanced (**transfemoral**) into the valve apparatus allowing **automatic** anatomic alignment in the aortic sinuses and claspings of the native valve leaflets (Figure 1C), **this can be visualised on fluoroscopy**. Once positioned, the self-expanding valve is then deployed within the anchor rings and secures the native valve leaflets (Figure 1D). **The valve is not recapturable**. The transfemoral (**TF**) valve is delivered by an 18Fr steerable delivery system (Figure 1B). We present the first-in-human experience of the **TF** J-Valve system for the treatment of severe AR.

## Methods

A 42-year-old male with prior subaortic membrane repair presented with recurrent heart failure hospitalizations due to severe AR (New York Heart Association (NYHA) Class IV) and high diuretic requirements. Echocardiography revealed normal (LV) systolic function, an LV end-diastolic diameter of 66mm and a non-calcified tricuspid aortic valve with severe AR (Figure 2A). Invasive cardiac catheterization revealed normal coronary arteries and raised LV end-diastolic pressure of 35mmHg. He had multiple comorbidities including morbid obesity (BMI >50kg/m<sup>2</sup>), diabetes and stage IV chronic kidney disease (eGFR 29ml/min per1.73m<sup>2</sup>). STS predicted risk of mortality was 7.8% and the patient was deemed at prohibitive risk for surgical aortic valve replacement or TA TAVI by the multidisciplinary Heart Team. **Preoperative valve sizing with**

*Disclaimer : As a public service to our readership, this article -- peer reviewed by the Editors of EuroIntervention - has been published immediately upon acceptance as it was received. The content of this article is the sole responsibility of the authors, and not that of the journal*

**computed tomography was not optimal due to elevated body mass index and attempts to reduce contrast load to lower the risk of acute kidney injury, therefore intraoperative transesophageal echocardiography (TEE) was performed to confirm sizing. TEE is not required for deployment of the valve.**

Right common femoral arterial access was gained and an 18F sheath inserted. The aortic valve was crossed and a small Safari wire (Boston Scientific, Marlborough, Massachusetts, USA) was placed in the left ventricle. A 28mm J-valve system was advanced over the wire into the aortic root and deployed without the need for rapid pacing. Deployment of the valve proved challenging due to the small size of the sinotubular junction which interacted with the valve's anchor rings, however a stable position was attained (Figures 2C and 2D). Following valve deployment there was an immediate improvement in haemodynamics. Echocardiography and aortography revealed no significant AR (Figure 2B), however the aortic portion of the valve frame appeared under-expanded on fluoroscopy (Figure 2D). **We believe that this was due to rotation of the delivery system following deployment of the anchor rings, but prior to valve deployment, resulting in the twisting of suture connections at the top of the valve.** Mean transaortic gradient on transthoracic echocardiography (TTE) was 39mmHg with no AR. Post-dilatation of the TAVI valve was subsequently performed with a 25mm balloon and resulted in full expansion of the valve frame and a reduction of the mean gradient to 16mmHg (Figures 2E and 2F).

## **Results**

The patient remained intubated for 8 days due to high respiratory support requirements and required temporary intermittent haemodialysis. On discharge the patient was euvolaemic, had NYHA class II symptoms, improved renal function (eGFR >50) and no diuretic requirements. At 30-day follow-up the patient remained NYHA Class II and remained off diuretics. TTE revealed a mean gradient of 18mmHg with no AR and normal LV systolic function.

*Disclaimer : As a public service to our readership, this article -- peer reviewed by the Editors of EuroIntervention - has been published immediately upon acceptance as it was received. The content of this article is the sole responsibility of the authors, and not that of the journal*

## Discussion

The J-Valve TF system offers potential for the treatment of **severe AS and pure AR** and despite a difficult post-procedural course, delivered a promising clinical result in this case. **Under-expansion of the valve, as occurred in this case, can be prevented by avoiding rotation of the delivery system after deployment of the anchor rings. Changes to the delivery system are also being made to address this issue.** A TF approach is less invasive than TA access whilst preserving the leaflet-securing and anatomic positioning abilities of the J-Valve system. These leaflet-securing properties offer possible advantages, not only in the treatment of pure AR, but also may also offer a solution to the treatment of patients with either native AS or bioprosthetic valve failure at high risk of coronary obstruction as the anchor rings may retract the native or bioprosthetic valve leaflets to avoid obstructing the coronary ostia (3); this requires further investigation. **Additionally the valve to date has demonstrated a low pacemaker rate of approximately 5% (1, 2), likely due to the relatively high deployment within the anchor rings.**

## Limitations

This is a single case study and the TF J-Valve system requires validation with further clinical data and large-scale clinical trials.

## Conclusions

The TF J-Valve system is a novel transcatheter heart valve system with leaflet securing anchor rings, which may be well suited to patients with non-calcified aortic valve disease and those at risk of coronary obstruction. Further clinical experience is required.

## Impact on daily practice

The TF J-Valve is not currently available outside of clinical studies, however it is a potentially advantageous device in certain clinical situations.

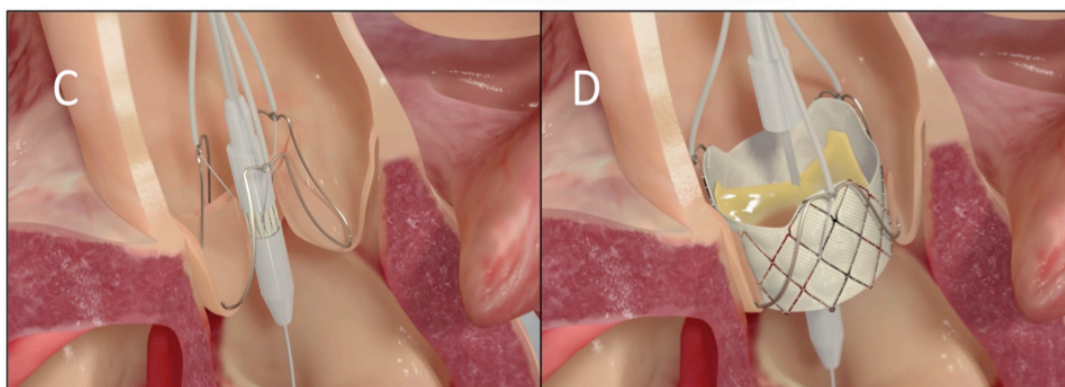
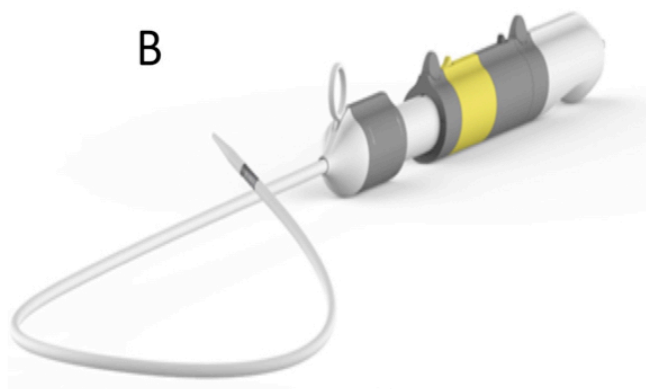
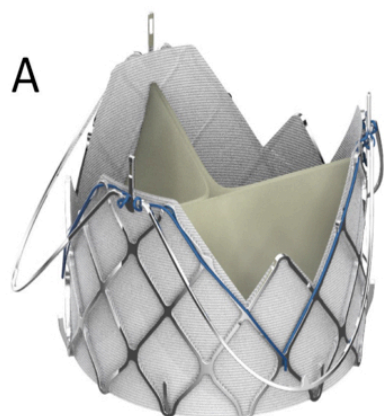
**Figure 1.** Transfemoral J-Valve System. A) Valve consisting of bovine pericardial leaflets within nitinol stent frame deployed within nitinol anchor ring. B) J-Valve steerable transfemoral delivery system. Outer diameter of 18Fr with minimal femoral access diameter of 5.5mm. C) Illustration of anchor ring deployment within native valve cusps with anatomic alignment and leaflet grasping. D) Deployment of self-expanding J-Valve within anchor ring. E) Valve sizing chart. A 31mm valve is also in development

**Figure 2.** Transesophageal echocardiography (TEE) and fluoroscopy of J-Valve deployment. A) TEE pre-deployment showing severe aortic regurgitation. B) TEE post-deployment showing trivial paravalvular aortic regurgitation. C) Fluoroscopy of anchor deployment into native valve cusps. D) Fluoroscopy of deployed valve into anchor rings. E) Post-dilatation of valve with 25mm non-compliant balloon. F) Final aortogram showing well-deployed valve with no aortic regurgitation.

## References:

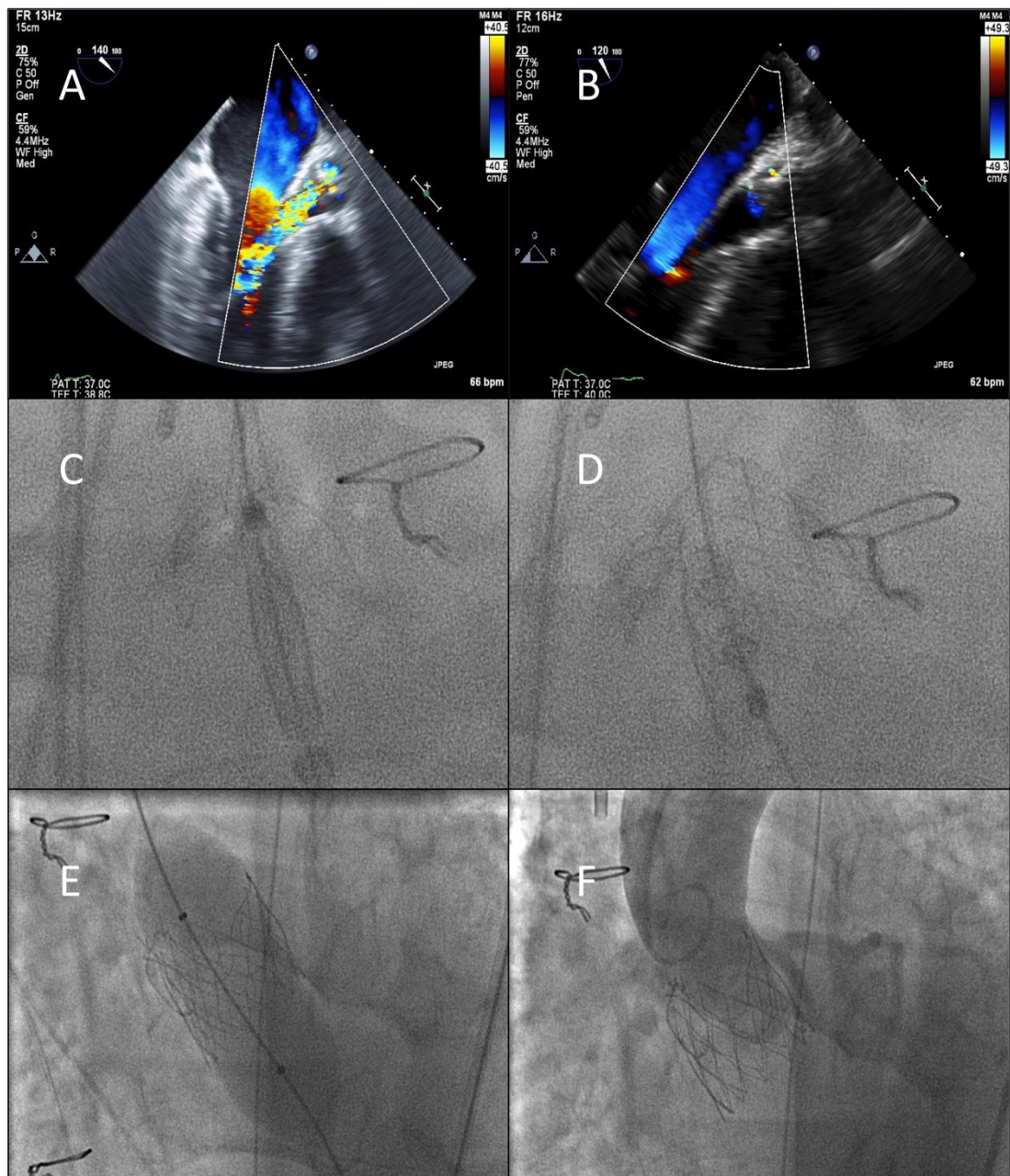
1. Liu H, Yang Y, Wang W, Zhu D, Wei L, Guo K, Zhao W, Yang X, Zhu L, Guo Y, Wang W, Wang C. Transapical transcatheter aortic valve replacement for aortic regurgitation with a second-generation heart valve. The Journal of thoracic and cardiovascular surgery. 2018;156(1):106-16.
2. Zhu L, Guo Y, Wang W, Liu H, Yang Y, Wei L, Wang C. Transapical transcatheter aortic valve replacement with a novel transcatheter aortic valve replacement system in high-risk patients with severe aortic valve diseases. The Journal of thoracic and cardiovascular surgery. 2018;155(2):588-97.
3. Ye J, Lee AJ, Blanke P, Webb J. The first transapical transcatheter aortic valve-in-valve implantation using the J-valve system into a failed biophysio aortic prosthesis in a patient with high risk of coronary obstruction. Catheterization and cardiovascular interventions : official journal of the Society for Cardiac Angiography & Interventions. 2018.





**E**

Valve Size	Annulus Diameter	Annulus Perimeter	Annulus Area
22mm	18-21 mm	57.3-66.6 mm	262-353 mm <sup>2</sup>
25mm	21-24 mm	65.1-75.9 mm	337-458 mm <sup>2</sup>
28mm	24-27 mm	72.8-85.0 mm	422-574 mm <sup>2</sup>



**Disclaimer :** As a public service to our readership, this article -- peer reviewed by the Editors of EuroIntervention - has been published immediately upon acceptance as it was received. The content of this article is the sole responsibility of the authors, and not that of the journal